
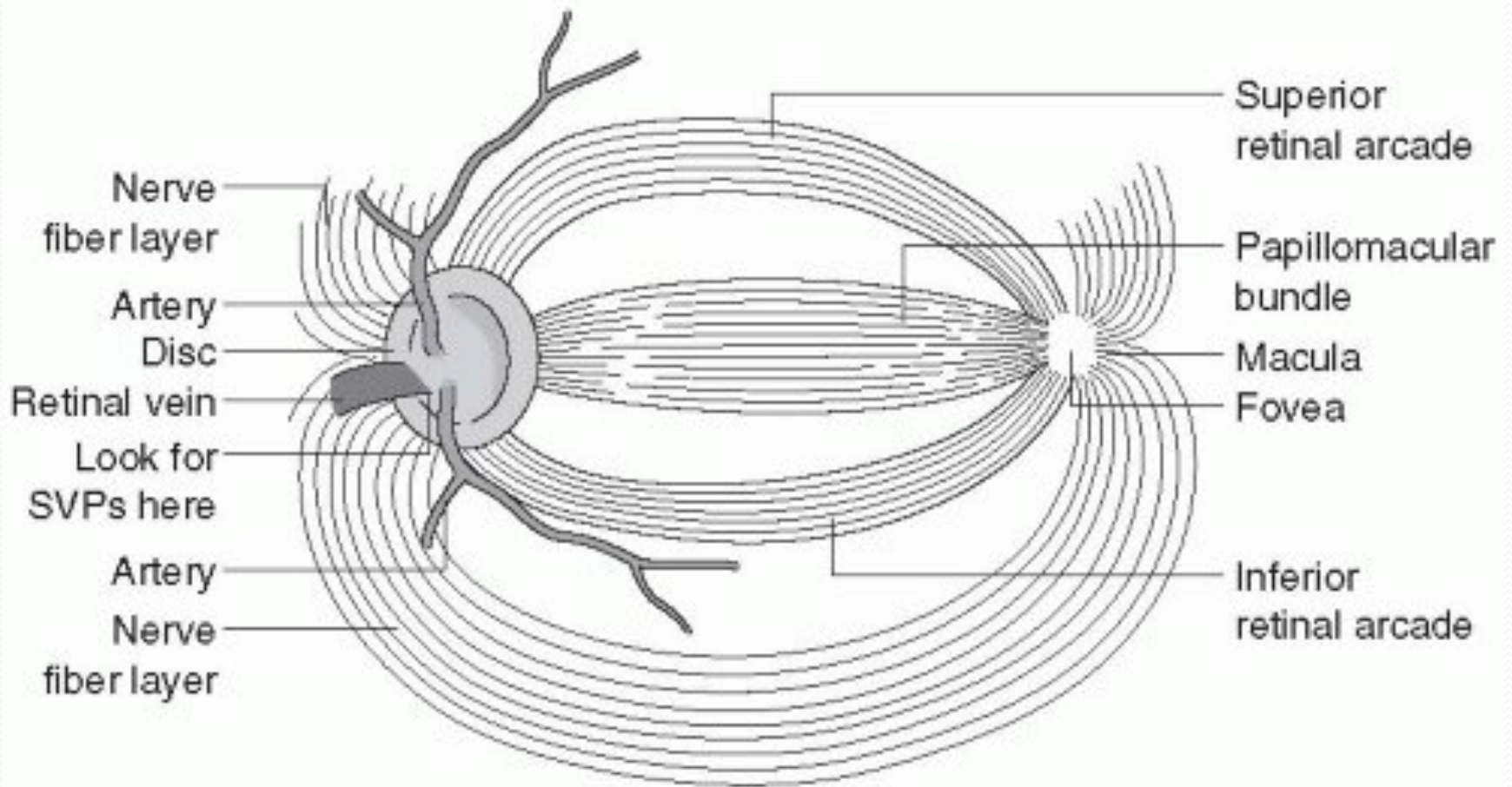


OPTIC NERVE : APPLIED ANATOMY, CLINICAL EVALUATION AND APPROACHES

Anatomy

- CNS fibre pathway connecting brain and retina
- Axons of ganglion cells
- Optic disc: ophthalmoscopically visible tip of intraocular portion of optic nerve.
 - 1.5x1.8 mm vertical ellipse (*YELLOWISH PINK*)
 - No receptors (blind spot)
- Macula – centre of retina/centre of clinical visual field
 - Central 15° of vision/no rods/color vision/fine vision
- Myelin formed by oligodendroglia(at posterior end of optic nerve head)
- In 1% extends to peripapillary retinal nerve fiber layer (myelinated nerve fibers)

- 
- 90% of fibers arise from macula
 - Early signs of optic nerve disease reflect macular function (impaired color vision, impaired acuity and central scotoma)



De Jong's The Neurologic examination

- 50 mm long and has four portions from the globe to the chiasm
- Flattened horizontal oval shape measuring 4x6 mm when at chiasma. After it enters the cranial end of the optic canal, it is circular and 5 mm in diameter, and continues to the globe as a 6 x 4 mm, vertically oval structure
- Pia-chiasma to globe
- Arachnoid-fuses with pia at globe
- The dura mater when it reaches the foramen splits in periosteum and fibrous sheath of the nerve. This arrangement prevents pus, forming in the orbit, from passing through the optic foramen into the skull

Four parts

- Intraocular part (1 mm), also known as the optic nerve head
- Intraorbital part (25 mm)
- Intracanalicular part (5 mm)
- Intracranial part (10 mm)

- ***Intraocular Portion.*** *In this portion, also called the optic nerve head (1 mm long), the axons become myelinated (central type of myelin)*

Intraorbital Portion

- This (*section 25 mm long*) is shaped like an elongated S to allow mobility within the orbit
- Here the optic nerve is surrounded by fat contained in the cone formed by the ocular muscles
- Optic nerve passes below the levator and superior rectus muscles
- The apex of this cone (which is open to the optic foramen and the superior orbital fissure) is directed posteriorly and slightly displaced naso-superiorly in the orbit
- In addition to the ophthalmic artery, the ciliary ganglion and nerves, and the nerves to the extraocular muscles are in close relation to the optic nerve here.

Intracanalicular Portion

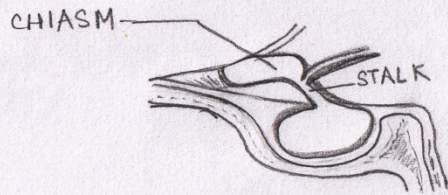- This portion (*approximately 9mm long*) is the part of the nerve that travels the optic canal.
- Each optic canal is oriented posterosuperomedially, at an angle that approximates 45 degrees to the sagittal and horizontal planes. The ophthalmic artery and some filaments of the sympathetic carotid plexus accompany the optic nerve within the optic canal

- Although the intraorbital segment of the optic nerve is permitted limited motion, the intracanalicular portion of the optic nerve is tethered within the optic canal
- Thus, the intracanalicular nerve is at risk for both primary and secondary ischemic injury caused by shearing and swelling within the fixed cross-sectional area of the bony canal

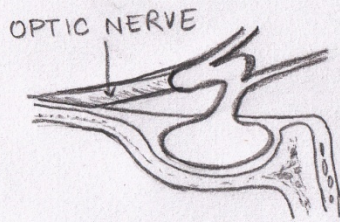
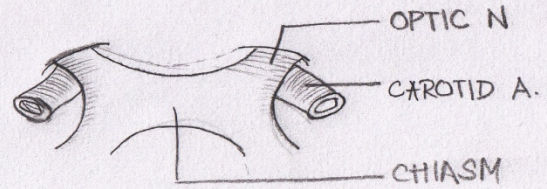
Intracranial Portion

- *This part (approximately 16mm long, depending on the position of the chiasm) stretches between the proximal opening of the optic canal and the chiasm*
- *directed posterior, superiorly, and medially toward the optic chiasm*
- *Each optic nerve lies above the respective carotid artery as this vessel exits from the cavernous sinus and gives off the ophthalmic artery*
- *Inferomedially, the optic nerve lies over the bony roof of the sphenoid sinus, which can be quite thin, and over the contents of the sella turcica when the chiasm is posteriorly placed*
- *Superior to each optic nerve is part of ACA, which is overlaid by the gyrus rectus of the frontal lobe, the olfactory tract, and the anterior perforated substance*
- *The anterior communicating artery is superior to the optic nerves or to the optic chiasm. Proximal to the angled optic canal, the optic nerves maintain a 45-degree angle to the horizontal plane*

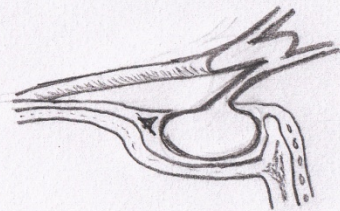
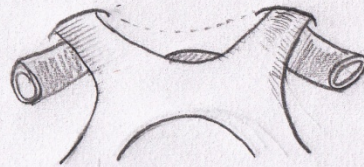- Chiasm is tilted over the sella turcica, with the suprasellar cistern lying between them
- The relation between the chiasm and the sella varies between individuals
 - In brachycephalic heads the chiasm tends to be more anterior and dorsal than in dolichocephalic heads
- In 80% chiasm is above central part of diaphragma sella (normal). In 9% it lies anteriorly over tuberculum sellae (prefixed) and in 11% it is situated posteriorly over posterior clinoids (post-fixed)



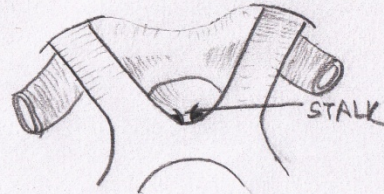
PREFIXED



NORMAL



POSTFIXED




Relationship in the orbit

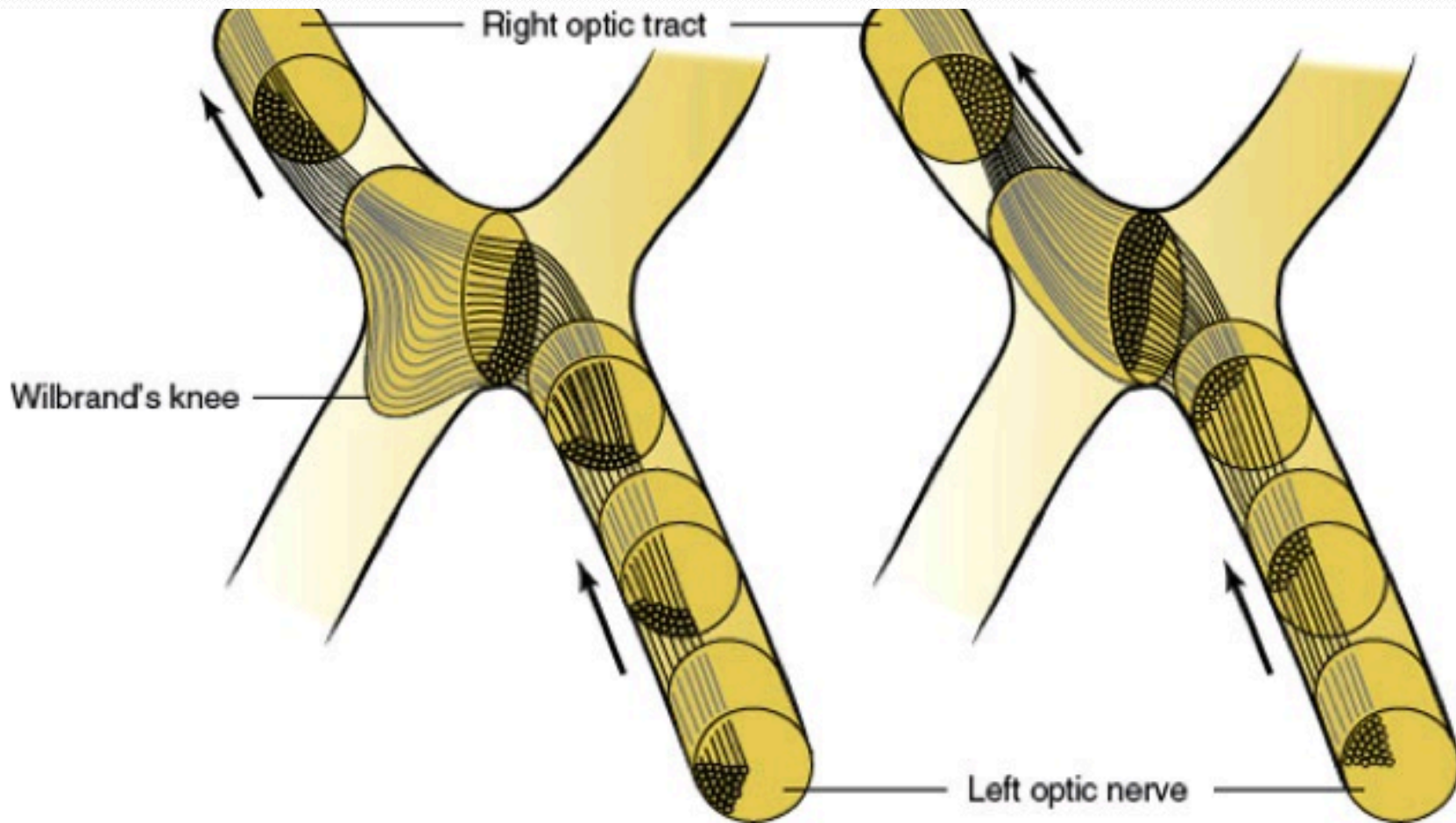
- The ophthalmic artery enters the orbit on the lateral side of the nerve and passes above the nerve to reach the medial sides of the orbit
- The superior ophthalmic vein arises in the anteromedial part of the orbit and crosses above the nerve to reach the orbital apex
- Both the artery and vein course between the superior rectus muscle and the optic nerve
- The branch of the inferior division of the oculomotor nerve to the medial rectus muscle passes below the optic nerve at about the same level that the ophthalmic artery and nasociliary nerve pass above the optic nerve

Topical arrangement

- Nerve fibers in the optic nerve follow a topical arrangement similar to that found in the retina
- Superior retinal fibers run superiorly in the optic nerve, inferior fibers are below
- Those from the temporal and nasal retina run in the corresponding parts of the optic nerve

- 
- In the proximal portion of the nerve, near the globe, the macular fibers occupy a wedge-shaped sector just temporal to the central vessels More distally, they shift toward the core of the nerve

- At the chiasm, more than half of the fibers (those originating in ganglion cells of the nasal retina) cross to reach the contralateral optic tract
- The ratio of crossed to uncrossed fibers is approximately 53:47
- Fibers from the inferior part of the nasal retina are ventral in the chiasm and loop into the proximal portion of the contralateral optic nerve (*Wilbrand's knee*) before reaching the lateral aspect of the optic tract . Those from the superior nasal retina remain dorsal in the chiasm and become medial in the optic tract



- Uncrossed fibers, originating from the temporal retina, maintain their dorsal or ventral position in the chiasm
- The macular fibers, which constitute a large proportion of the total number of chiasmal fibers, are also crossed and uncrossed
- The separation between temporal and nasal ganglion cells is not sharp
- Crossed and uncrossed fibers originate in both nasal and temporal sides of the macula.
- In the optic tract, the macular fibers occupy a dorsal position

Vascular Supply of the Visual Pathways

- The vascular supply of the retina is derived from the ophthalmic artery, which branches from the carotid artery shortly after this vessel exits from the cavernous sinus
- At the optic canal, the ophthalmic artery lies below and lateral to the nerve
- At a point 5mm to 15 mm from the globe, it gives off the central retinal artery, which pierces the optic nerve and courses forward in its core, to divide into a superior and an inferior branch
- At the optic disc second-order nasal and temporal branches supply the nerve fiber layer and the inner layers of the retina (including ganglion cells)

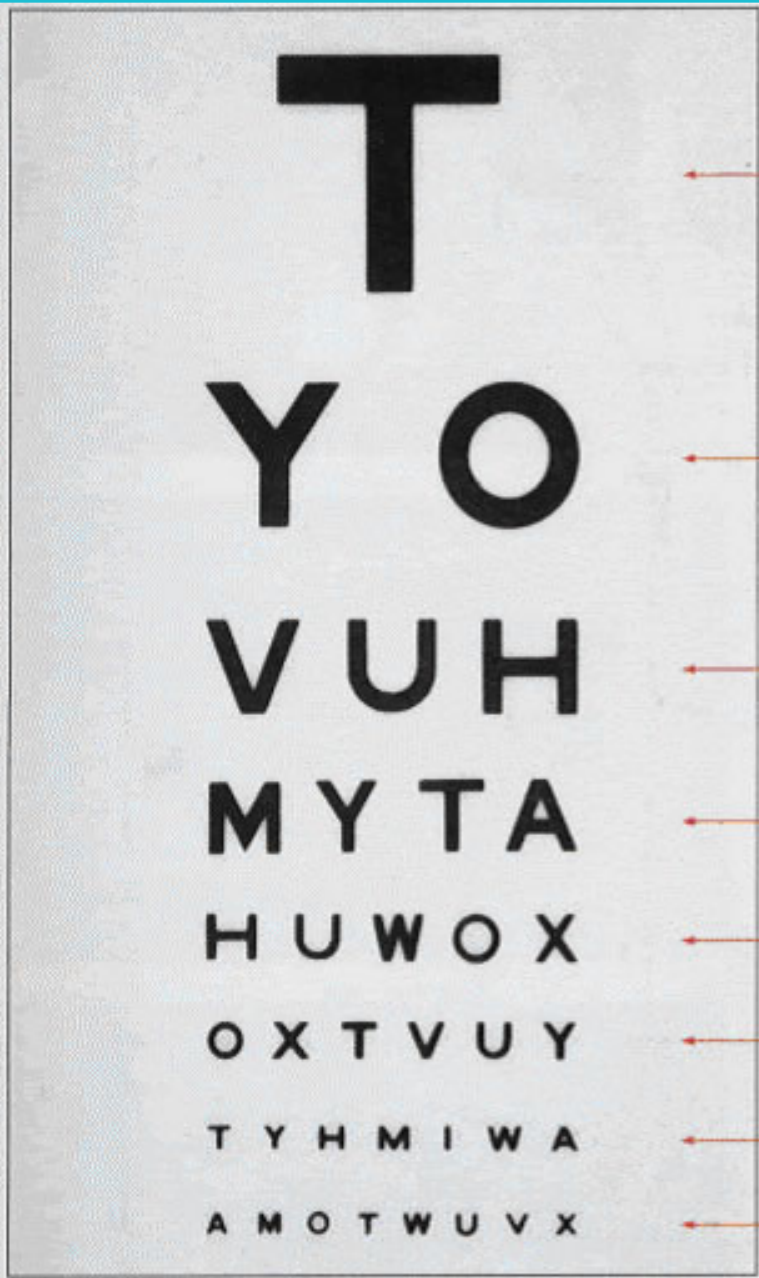
- The distal part of the optic nerve (near the globe) is supplied by small branches of the ophthalmic artery and, as it approaches the chiasm, by thin vessels from the carotid and anterior cerebral arteries.
- Similarly, thin vessels originating in the region of the anterior communicating artery supply the dorsal aspect of the chiasm, whereas the inferior aspect receives arterioles from the carotid, posterior communicating, and posterior cerebral arteries.
- The latter two vessels also supply the optic tract, which in addition is fed by the anterior choroidal artery

Clinical evaluation

- Visual acuity
- Color vision
- Visual field
- Pupillary evaluation
- Fundus examination

Visual Acuity

- *Visual acuity, the capacity for visual discrimination of fine details of high contrast, such as small black letters on a white page, reflects the function of the macular region*
- Distant vision is tested using the snellen's chart
- Near vision(near card held at 35 cm)
- Visual acuity is expressed as 'd/D'. d is the distance of which the patient sits is 6m. 'D' no of the line that patient can read
- Best corrected visual acuity should be noted
- A subnormal value of acuity indicates a fault in the visual system (e.g., optical faults, retinal lesions, or visual pathway lesions), faulty foveation (i.e., an eye motility defect), or poor cooperation, singly or in combination
- It remains unimpaired by unilateral lesions dorsal to the optic chiasm
- Most common cause : refractive error



← 6/60

← 6/36

← 6/24

← 6/18


← 6/12

← 6/9 Approximate level of acuity for driving

← 6/6 Normal distance vision at 6 metres

← 6/5

Snellen Chart

- 
- The macula is the only part of the retina that has high visual acuity
 - Virtually, all compressive and most noncompressive lesions of the *optic nerve cause a drop in visual acuity*, often even before a field defect can be detected.
 - Unilateral lesions of the *optic tract, lateral geniculate body, visual radiations, or striate cortex do not impair visual acuity*
 - When the retrochiasmal pathways are affected bilaterally, visual acuity fails to the same degree in both eyes

Perception of Colour

- *Loss of colour vision may precede other visual deficits*
- More decreased in optic nerve disorders than retinal disorders
- *Colour perception is often degraded in areas of the visual fields that correspond to a partial field defect*
- In neurologic diseases red perception is lost first
- Scotoma for blue or for red may be demonstrated when vision for white targets is still good
- In confrontation testing of the visual fields, one of the most useful techniques is to ask the patient which one of two identically bright red objects is more red, (subjective afferent pupillary defect)
- A colour sample that appears red to the healthy eye appears more yellowish to the defective eye and passes from orange to yellow to colourless as disease severity increases
- Ishihara or Hardy-Rand-Rittler pseudoisochromatic colour plates

- Colour-blind patients cannot perform this task, which mainly reflects macular function
- Because optic nerve and chiasmatic lesions often affect the macular fibers, monocular reading of the Ishihara or similar plates may be defective on the side of the lesion
- The Farnsworth panel D-15 test consists of 15 colour caps randomly placed in front of the patient with the reference cap. The patient is told to arrange the caps in an orderly transition of hue

Pupillary evaluation


- Size
- Magnitude and the latency of the direct and consensual responses to light and near stimulation. A relative afferent pupillary defect (RAPD) is a hallmark of unilateral afferent sensory abnormality or bilateral asymmetric visual loss
- Occasionally, RAPD is the only objective sign of anterior visual pathway dysfunction
- It is a sensitive optic nerve function test
- Clinically, it is graded as follows:
 - Immediate dilation of the pupil, instead of normal initial constriction (3-4+)
 - No changes in initial pupillary size, followed by dilation of the pupils (1-2+)
 - Initial constriction, but greater escape to a larger intermediate size than when the light is swung back to normal eye (trace)

Visual Fields

- The shape and distribution of *visual field loss* closely *reflects the site* of the lesion
- Careful plotting of the visual fields is most helpful in the localization of lesions of the visual pathways when examining a cooperative patient
- Depicted as seen by patient (right eye drawn on right)
- Central visual field, which has a 30-degree radius
- beyond 30 degrees is peripheral visual testing
- The central visual field can be tested using, confrontation techniques, amsler grid, tangent screen
- Peripheral visual testing includes automated perimetry and manual perimetry (goldman perimeter). Automated perimetry (static perimeter) more frequently used

Confrontation method

- Sit 2 ft in front of patient
- Screening method-small amplitude finger movement in periphery binocularly
- Monocular examination:
 - Use varying objects-still or moving fingers, colored pinheads
 - Same horizontal level
- Low sensitivity (5mm red target > red color intensity > finger counting) but high specificity
- For uncooperative, obtunded subjects use paper money as object

- 
- In bedridden, uncooperative demented subject, defensive eye blinking brought by moving the examiner's hand rapidly from periphery towards patients eye can be tested
 - Absence of expected response should suggest loss of vision in that part of visual field
 - Adequate visual field testing requires patient cooperation and a skilled examiner

Types of VF defects:

1. Scotomas (area of impaired vision with normal surrounding)
2. Hemianopia (impaired vision in half visual field of each eye)
3. Altitudinal defects (by vascular diseases-sharply demarcated horizontally)
4. Concentric constriction of field

Neurological disorders produce straight edged defects that respect horizontal or vertical meridian

Localization of Visual Field Defects

- Most important for lesion localization, is to note whether the field defect is *monocular*, in which case the lesion usually affects the retina or the optic nerve, or *binocular*, in which case the lesion is localized to or beyond the optic chiasm
- The pattern of the visual field loss can seldom differentiate retinal from optic nerve disease
- However, retinal involvement generally accompanies obvious ophthalmoscopic abnormalities
- Most optic neuropathies involve visual acuity
- Spared acuity should raise the suspicion of preretinal, retinal, or retrochiasmal disease

- *Monocular visual field defects are almost always due to disease of, retina, optic disc, or optic nerve*
- *Central visual field defects (unilateral or bilateral) are the result of damage to the papillomacular bundle or optic nerve*
Any visual field defect produced by a retinal lesion may be produced by a lesion of the optic nerve and virtually any etiology may be responsible
- *Central/paracentral/cecocentral scotoma can result. Any scotoma involving blind spot implies optic neuropathy*


- Although monocular visual field defects are usually due to retinal or optic nerve disease, in the early stages of a chiasmatic lesion, the loss may be restricted to the temporal portion of the field corresponding to the ipsilateral eye
- This monocular (often scotomatous) temporal hemianopia (*junctional scotoma of Traquair*, is attributed to the involvement of the ipsilateral optic nerve close enough to the chiasm to impair conduction selectively in ipsilateral crossing fibers but too anterior to affect nasal retinal fibers crossing from the fellow eye (i.e., nasal compression of the distal intracranial optic nerve ipsilateral to the defect)

- *Bitemporal field defects* are most often due to a compressive mass lesion affecting the optic chiasm, such as pituitary tumors
- Rarely, processes that cause rapidly developing hydrocephalus in children may result in bitemporal defects, perhaps through dilation of the optic recess of the third ventricle
- True pure complete bitemporal hemianopias are rare because it is difficult for any pathogenetic mechanism to affect crossing fibers only. Bitemporal hemianopsia may be peripheral, paracentral, or central
- Other causes: meningioma, craniopharyngioma, optic nerve, aneurysm, trauma, hydrocephalus

- Three chiasmatic syndromes may be recognized
- **The *anterior chiasm or junctional syndrome*** (different from the junctional syndrome of Traquair,), in which a unilateral optic defect is associated with a superior temporal defect in the other eye.
- ***Body of the chiasm syndrome***, in which patients demonstrate bitemporal visual field defects. These visual field defects may be peripheral, central, or a combination of both, with or without splitting of the macula, and may be quadrantic or hemianopic.
 - Visual acuity is usually normal, and the optic discs are normal or pale.
- **The *posterior chiasm syndrome***, in which visual field testing reveals bitemporal scotomas (the peripheral visual fields are intact). Visual acuity and the optic

- A *central defect in one field with a superior temporal defect in the opposite field* points to the involvement of the anterior angle of the chiasm, with damage of the ipsilateral optic nerve and of the loop made by the fibers from the inferonasal retina of the other eye (Wilbrand's knee). Because of its localizing implications, this type of visual field defect has been termed *junctional scotoma* (different from the *junctional syndrome of Traquair*,)

- *Binasal hemianopias and quadrantanopias may occur, are usually asymmetric, and often do not respect the vertical meridian*
- Binasal defects are usually due to bilateral intraocular disease of the retina or optic nerve (e.g., chronic papilledema, ION, glaucoma, optic nerve drusen, or retinal disease such as sector retinitis pigmentosa or retinoschisis). Bilateral nasal defect may occur
 - With hydrocephalus with third ventricle enlargement causing lateral displacement of optic nerves against the supraclinoid portion of the internal carotid arteries
 - Bilateral ICA aneurysm
- Binasal defects have also been described in patients with primary empty sella syndrome and with other suprasellar lesions

- 
- Patients with lesions in the anterior optic pathways usually complain of difficulty in reading and the dimming of vision.
 - Altitudinal field defects are often described as a curtain coming down or the sensation of looking over the horizon.
 - Vertical hemianopic defects are often detected when the patient finds himself colliding with objects in the blind field or is unable to see half of the page or the keyboard.
 - Patients with chiasmatic lesions and bitemporal hemianopia may lose central vision when their eyes converge, because convergence makes the bitemporal defects overlap.



Fundus Examination

- Ask patient to fixate on distance object
- Quickly look from 10 cm with plus for red reflex and anterior segment
- Horizontal plane like patients eye ,about 15 degree from line of fixation. Aim at centre of back of patient's head
- Examine structures in a methodical sequence
Disc (think of the 3 Cs : cup, colour and contour)
 - Macula
 - Vessels
 - Periphery
 - Vitreous

- Normal disc is flat, yellowish - pink ellipse from which vessels radiate(usually 4)
- Disc consists of peripheral neuroretinal rim and central cup
- normally nasal margin blurred
- Temporal pallor
- Macula 2D temporal to disc

- The optic nerve enters the eye about 3mm nasally to the fovea in each eye
- The normal disk is 1.5 to 2.0 mm across and may be nearly round or oval in shape
- Depression in the center of the normal nerve called the physiologic cup
- Below the cup, the nerve fibers pass through a membrane with many small holes in it, called the lamina cribrosa. Normally, the lamina is hidden by nerve fibers and cannot be seen when viewing the nerve from above
- A C/D of 0.3 is considered to be normal

Papilledema

- Papilledema is optic disc swelling that is secondary to elevated intracranial pressure
- In contrast to other causes of optic disc swelling, vision usually is well preserved with acute papilledema
- Papilledema almost always presents as a bilateral phenomenon and may develop over hours to weeks

- As intracranial pressure increases, axonal transport in the optic nerve is impeded in the prelaminar area, causing the optic nerve to distend
- As the nerve head swells forward into the vitreous, concurrent swelling occurs laterally, causing Paton's folds (retinal folds or lines) circumferentially around the optic nerve head
- Swollen axons impair venous drainage from retina engorging capillaries and then retinal veins ultimately causing splinter and flame shaped haemorrhages
- *FURTHER AXONAL SWELLING LEADS TO ELEVATION OF DISC ABOVE RETINAL SURFACE*

- 
- During infancy, before the fontanelles close, the finding of papilledema may fail to occur despite elevated intracranial pressure

Symptoms

- Secondary to the underlying elevation in intracranial pressure
- Headache and vomiting
- Pulsatile tinnitus
- Usually preserved visual acuity and colour vision (early)
- Some patients experience transient visual obscuration (graying-out of their vision, usually both eyes, especially when rising from a lying or sitting position, or transient flickering as if rapidly toggling a light switch)
 - Blurring of vision, constriction of the visual field, and decreased colour perception may occur
 - Diplopia may be seen occasionally if a sixth nerve palsy is associated.
 - Visual acuity well-preserved, except in very advanced disease
- No afferent pupillary defect until disc edema is severe and asymmetric
- Sometimes found at examination in an asymptomatic individual

Physical

- Early manifestations
 - Disc hyperaemia ((dilatation of capillaries in the disc surface)
 - Subtle edema of the nerve fiber layer can be identified with careful slit lamp biomicroscopy and direct ophthalmoscopy. This most often begins in the area of the nasal disc. A key finding occurs as the nerve fiber layer edema begins to obscure the fine peripapillary vessels.
 - Small hemorrhages of the nerve fiber layer are detected most easily with the red-free (green) light
- Spontaneous venous pulsations that are normally present in 80% of individuals may be obliterated when the intracranial pressure rises above 200 mm water
- Though the presence of spontaneous venous pulsations is very useful to exclude papilledema , its absence is not very helpful
- The presence of venous pulsations synchronous with the arterial pulse is a reliable indicator of intracranial pressure below 180 to 190 mm of water

- Late manifestations

- As the papilledema continues to worsen, the nerve fibre layer swelling eventually obscures the normal disc margins and the disc becomes grossly elevated
- Venous congestion develops, and peripapillary haemorrhages become more obvious, along with exudates and cotton-wool spots
- The peripapillary sensory retina may develop concentric or, occasionally, radial folds known as Paton lines. Choroidal folds also may be seen

- Chronic manifestations

- If the papilledema persists for months, the disc hyperemia slowly subsides, giving way to a gray or pale disc that loses its central cup
- With time, the disc may develop small glistening crystalline deposits (disc pseudodrusen)

- Striking optociliary shunt vessels may appear in the region of the
- Disc or at the disc margins in cases of chronic increased pressure in the optic canal or cranial cavity.
- Channels between the central retinal vein and the peripapillary choroidal venous system, which are enlarged in an effort to bypass the compressed venous channels of the optic nerve. They are most commonly seen with central retinal vein occlusion or optic nerve sheath meningiomas but also occur with optic nerve glioma, neonatal hydrocephalus, pseudotumor cerebri, drusen of the optic
- Disc, glaucomatous optic atrophy, high myopia, chronic atrophic
- Papillitis, arachnoid cyst of the optic nerve, neurofibromatosis
- Optic nerve coloboma, and osteosclerosis

Syndromes Causing Increased Intracranial Pressure

- *Primary causes*
 - Idiopathic pseudotumor cerebri syndrome (idiopathic intracranial hypertension) with papilledema
 - Idiopathic pseudotumor cerebri without papilledema
- *Secondary causes*
 - Hydrocephalus
 - Shunt failure in patient with hydrocephalus (ventriculomegaly may be absent)
 - Mass lesions e.g. tumor, hemorrhage, large infarction, abscess
 - Meningitis/encephalitis
 - Subarachnoid hemorrhage
 - Trauma
 - High flow arteriovenous malformations with overloading venous return
 - Intracranial or extracranial venous obstruction
 - Secondary pseudotumor cerebri syndrome due to certain systemic diseases, drugs, or pregnancy

The Stages of Papilledema

1. Early papilledema
 - Absence of venous pulsations
 - Minimal disc hyperemia with capillary dilation (*fiery red*)
 - Early opacification of nerve fiber layer (peripapillary retina loses its superficial linear and curvilinear light reflex and appears red without luster)
 - Early swelling of disc (*blurring of margins*)
 - Peripapillary retinal nerve fiber layer hemorrhage

2. *Fully developed papilledema*

- Disc surface grossly elevated
- Engorged and tortuous retinal veins
- May have splinter hemorrhages at or adjacent to the disc margin
- Surface vessels become obscured by now opaque nerve fiber layer
- Cotton wool spots/ *peripapillary hemorrhages*
- Paton's lines (circumferential retinal folds) or choroidal folds
- May have exudates (e.g., macular star or hemistar)
- May have hemorrhages or fluid in the macula that may decrease vision
- In acute cases (e.g., subarachnoid hemorrhage), subhyaloid hemorrhages may occur that may break into vitreous (Terson's syndrome)
- Rarely macular or peripapillary sub retinal neovascularisation

3. *Chronic papilledema*

- Haemorrhages and exudates slowly resolve (fewer)
- Central cup, which is initially retained even in severe cases, becomes completely obliterated
- Less disc hyperaemia
- Small hard exudates that are refractile and drusen-like may appear on disc surface
- Visual field loss including nerve fiber layer defects may develop
- Optociliary collateral vessels may develop

4. *Atrophic papilledema (pale disc edema)*

- Optic disc pallor with nerve fiber bundle visual field defects
- Retinal vessels become narrow and sheathed
- Occasional pigmentary changes or choroidal folds in macula
- Loss of peripheral axons
- Optic disc appears dirty gray and blurred secondary to gliosis

Frisen Papilledema Grading System

- Stage 0: Normal optic disc
- Stage 1
 - Obscuration of the nasal border of the disc
 - No elevation of the disc borders
 - Disruption of the normal radial nerve fiber layer (NFL) arrangement with greyish opacity accentuating nerve fiber bundles
 - Normal temporal disc margin
 - Subtle greyish halo with temporal gap
- Stage 2
 - Obscuration of all borders
 - Elevation of nasal border
 - Complete peripapillary halo

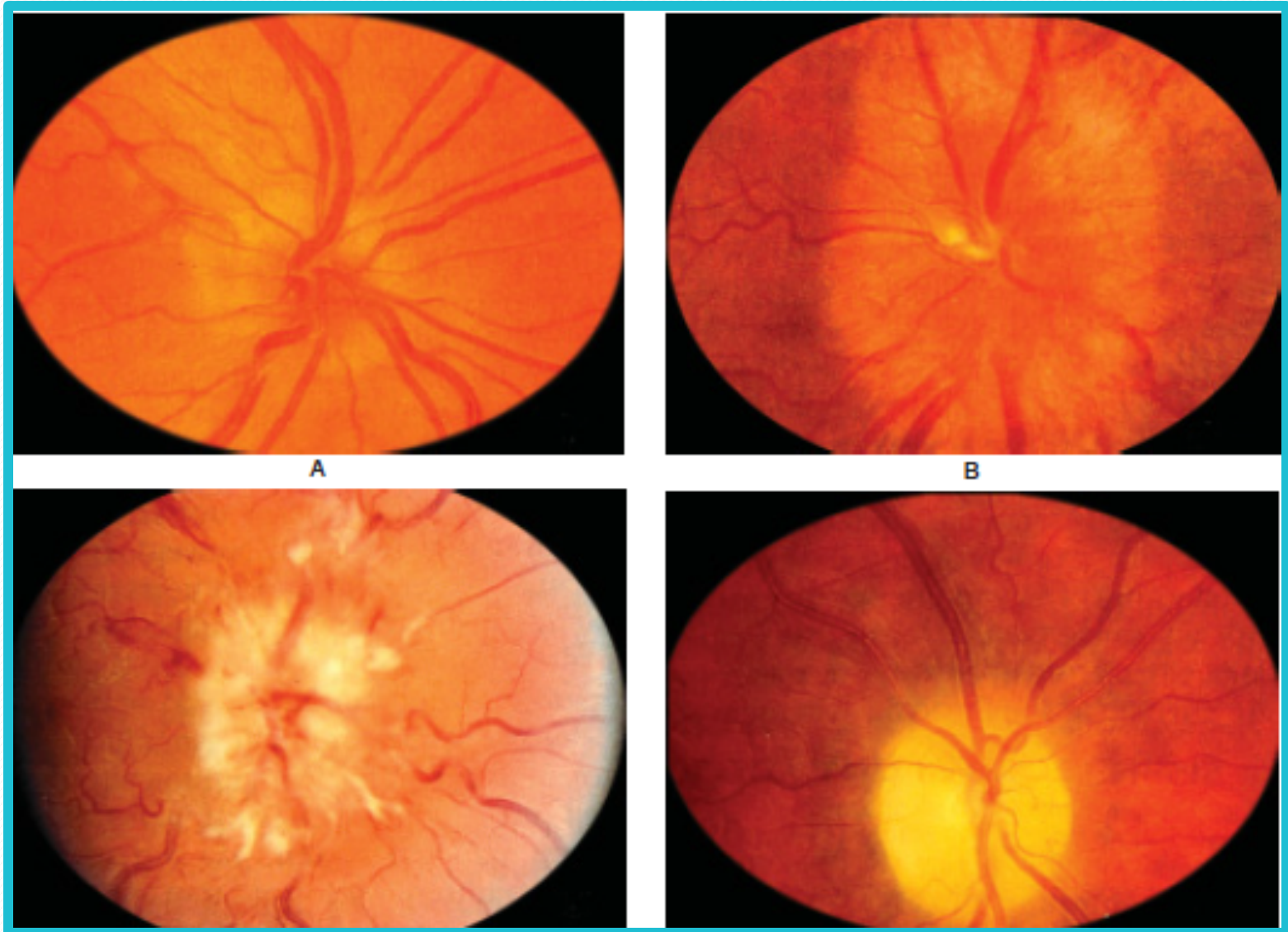
- Stage 3
 - Obscuration of all borders
 - Elevation of all borders
 - Increased diameter of the optic nerve head
 - Obscuration of one or more segments of major blood vessels leaving the disc
 - Peripapillary halo—irregular outer fringe with finger-like extensions
- Stage 4
 - Elevation of entire nerve head
 - Obscuration of all borders
 - Peripapillary halo
 - Total obscuration on the disc of a segment of a major blood vessel



- Stage 5

- Dome-shaped protrusions representing anterior expansion of the optic nerve head
- Peripapillary halo is narrow and smoothly demarcated
- Total obscuration of a segment of a major blood vessel may or may be present
- Obliteration of the optic cup

Papilledema showing blurred disc margins and dilated tortuous vessels



Differential Diagnosis

- True disc swelling must be distinguished from *Pseudopapilledema*
- *Striking disc changes of no clinical importance*
- *Anomalously elevated discs caused by optic nerve head drusen (in Caucasians)*
- Hyperopic discs
- Tilted discs
- *Myelinated nerve fibres*

Drusen of nerve head simulating papilledema

Primary optic atrophy

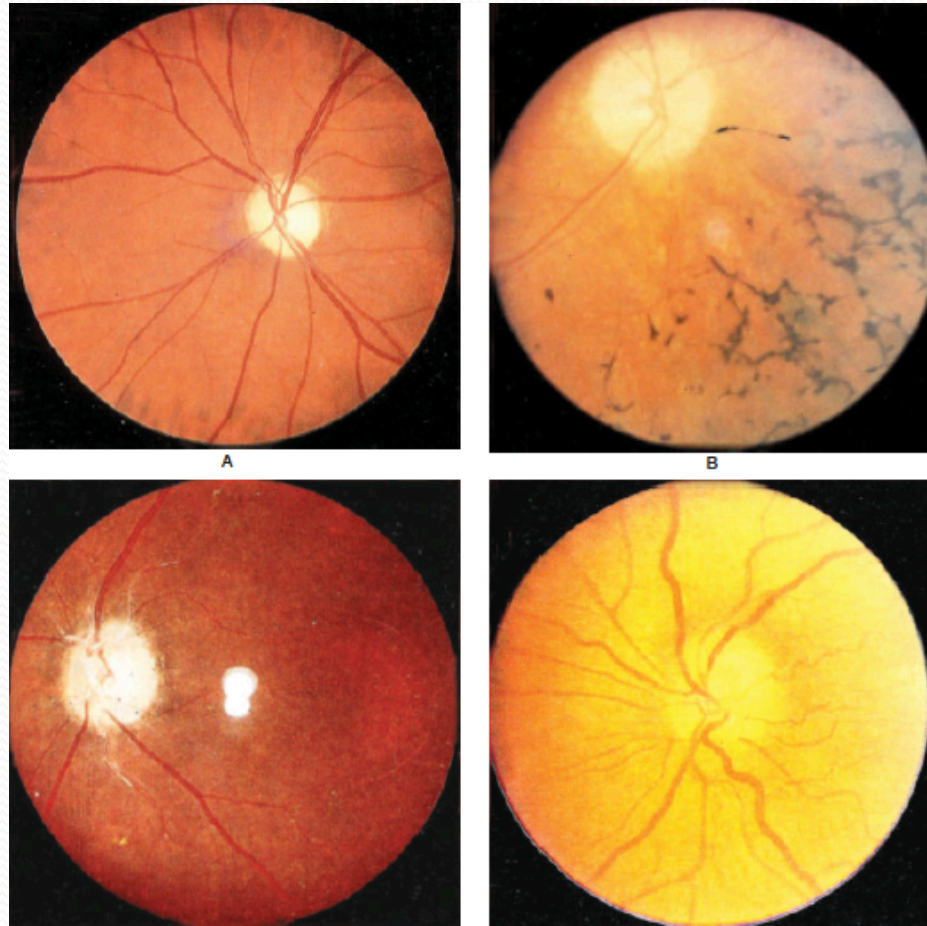


Figure: a) Primary, b) Consecutive, c) Postneuritic, d) Ischemic
Comprehensive Ophthalmology:Khurana

Optic Disc Edema

Disc vasculature obscured

Elevation of peripapillary NFL

Obscured peripapillary NFL

Venous congestion

Exudates/cotton wool spots

Loss of cup late

Normal disc vessels

No circumpapillary light reflex

Absent venous pulsations

Pseudopapilledema

Disc margin vasculature clear

Elevation confined to disc

Sharp peripapillary NFL

No venous congestion

No exudates/cotton wool spots

Small cupless disc

Anomalous disc vessels

Crescent circumpapillary light reflex

With or without spontaneous venous pulsations

- *Foster-Kennedy syndrome: ipsilateral optic atrophy and anosmia with contralateral papilledema.*
- Olfactory groove tumor (meningioma, inferior frontal glioma)

Tests

- Perimetry
 - They commonly show enlargement of the blind spot (normal is -elliptical 7~ vertically and 5~horizontally)
 - With extreme disc edema, a pseudo-bitemporal hemianopsia may be seen
 - Generalised constriction
 - Uncommonly Glaucomatous defects
 - With chronic papilledema, peripheral constriction of the visual field, especially nasally, gradually can occur, which eventually may progress to a loss of central acuity and total blindness
- Stereocolour photographs of the optic discs are useful to document changes

Fluorescein angiography

- Early disc capillary dilation, dye leakage, micro aneurysm formation
- Late leakage of dye beyond disc margins
- May be normal in early stages

Follow-up

- The patient should be examined weekly until stabilization of the ocular findings occurs. Well-developed papilledema takes 6-10 weeks to regress, following lowering of intracranial pressure

Prognosis

- The visual prognosis is generally good if the intracranial pressure is controlled

Optic Atrophy

- Final common morphologic endpoint of any disease process that causes axon degeneration in the retinogeniculate pathway
- Manifests as changes in the colour and the structure of the optic disc associated with variable degrees of visual dysfunction
- *Disc is pale, more sharply demarcated giving punched – out appearance*
- *Physiological cup is more prominent*
- the loss of capillaries causes the pale - appearing disc
- The Kestenbaum count is the number of capillaries observed on the optic disc. The normal count is approximately 10. In optic atrophy, the number of these capillaries reduces to less than 6; in a hyperemic disc, the count is more than 12

PRIMARY OPTIC ATROPHY

Secondary to other conditions e.g. optic neuritis, pituitary adenoma

Nerve fiber degenerate in orderly manner with preserved architecture of nerve head

Chalky white disc with sharply demarcated margins

Lamina cribrosa is well defined

Retinal vessels are normal

SECONDARY OPTIC ATROPHY

Secondary to papilledema


Marked degeneration with proliferation of glial tissue and altered architecture

Disc is dirty grey with poorly defined margins

Lamina cribrosa obscured due to proliferating glial tissue
Tortuous veins observed

Approaches

- Dandy described the frontotemporal craniotomy approach to the optic nerve. This procedure became the most frequently used surgery for for several decades
- The transcranial approach is commonly selected for tumors located in the orbital apex and/or optic canal, or involving both the orbit and adjacent intracranial area
- Those located in the apical area, and especially those on the medial side of the optic nerve, often require a transcranial approach

- 
- The orbitofrontal craniotomy would be selected for lesions involving the optic canal and orbital apex
 - One piece
 - Two piece
 - The orbitozygomatic craniotomy would be selected for orbital lesions involving the middle fossa or SOF

Opening

- The periorbita exposes the trochlear nerve and the supraorbital and supratrochlear branches of the frontal nerve, all of which course immediately beneath and can often be seen through the periorbita
- The trochlear nerve passes medially above the levator muscle to reach the superior oblique muscle
- Three routes through an orbitofrontal craniotomy can be taken to the orbital contents: medial, lateral, and central

- Space between the superior oblique and the levator muscles is much narrower than the space between the levator and the lateral rectus
- Lateral approach selected for lesions located superomedial to the optic nerve or for cases in which there is a need to expose the optic nerve from the optic canal to the globe
- It is the approach most commonly selected for tumors of the optic sheath or optic nerve
- The medial approach is not suitable for lesions located on the lateral side of the optic nerve or for those involving the superior orbital fissure and the cavernous sinus

The Medial Orbitofrontal Approach

- Between SO muscle, which is retracted medially, and the LPS and SR muscles, both of which are retracted laterally
- This approach exposes the optic nerve throughout the interval from the globe to the optic canal
- It is the most direct surgical approach to the apical part of the optic nerve
- The trochlear nerve, ophthalmic artery, nasociliary nerve, and superior ophthalmic vein, are *lateral to optic nerve at apex and* cross above the nerve
- The annular tendon and optic sheath exposes the medial and superior surface of the optic nerve from the globe to the optic chiasm
- This incision provides excellent exposure of the optic nerve and the ophthalmic artery in the optic canal and orbital apex

Central approach

- The levator muscle is retracted medially and the superior rectus muscle is retracted laterally
- *Least used*
- Most direct and shortest way to the midportion of the intraorbital segment of the optic nerve
- Structures seen in the exposure between the retracted muscles include the superior ophthalmic vein, ciliary arteries and nerves, nasociliary nerve, branch of the oculomotor nerve to the levator muscle, and the ophthalmic artery and its branches to the levator and superior rectus muscles
- The many structures in the exposure create a complicated field, requiring considerable care to avoid injuring the exposed structures

The Lateral Orbitofrontal Approach

- Between the LR muscle, which is retracted laterally, and the SR and LPS muscles, both of which are retracted medially
- Wider working space than the medial or central approach
- Best of the three orbitofrontal routes for exposing the deep apical area on the lateral side of the optic nerve
- Two variants of the lateral approach; the choice is determined by whether the superior ophthalmic vein is retracted medially or laterally

- Medial retraction of SOV - access to deep apical area is limited because the superior ophthalmic vein blocks the line of view
- Lateral retraction - provides access to lesions in the lateral part of the deep apical area that may also involve the superior orbital fissure and cavernous sinus
- *DISSECTION POSES RISK TO CRANIAL NERVES*

Lateral Wall Approach (Sphenozygomatic Approach)

- An approach directed through the lateral orbital wall, involving an osteotomy of the lateral orbital rim and wall
- Selected for tumors confined to the superior, temporal, or inferior compartment of the orbit and those in the lateral part of the apex
- Opening the periorbital wall exposes the lateral rectus muscle, the lacrimal artery and nerve, and the lacrimal gland. Retracting the orbital fat exposes the structures lateral to and above and below the optic nerve, and the insertion of the lateral rectus and inferior oblique muscles on the globe



Thank you